

# Laser Ureteral Anastomosis Using Intraluminal Albumin Stent in a Porcine Model

Hua Xie, MD, PhD,<sup>1\*</sup> Brian S. Shaffer, MD,<sup>2</sup> Scott A. Prah, PhD,<sup>1</sup> and Kenton W. Gregory, MD<sup>1</sup>

<sup>1</sup>Oregon Medical Laser Center, Providence St. Vincent Medical Center, Portland, Oregon

<sup>2</sup>Department of Urology, Providence St. Vincent Medical Center, Portland, Oregon

**Background and Objectives:** We compared ureteral anastomosis using a laser and intraluminal albumin stent with both conventional suturing and laser soldering techniques.

**Study Design/Materials and Methods:** Twelve pigs underwent bilateral ureteral anastomoses (N = 24) using one of the three anastomotic methods: (1) laser welding with intraluminal albumin stent (N = 11); (2) with albumin solder (N = 8); and (3) conventional suturing (N = 5). Operative parameters, leakage rate, intrapelvic perfusion pressure, urography, and histology of the anastomoses were examined.

**Results:** Operative time for ureteral anastomosis in the stent and solder groups were significantly shorter than the suture group (means 370 seconds and 360 vs. 710 seconds, both  $P = 0.02$ ). Leakage rate of the anastomoses was lower in the stent group (9%, 1/11) as compared to the solder group (25%, 2/8). The Whitaker test showed that the intrapelvic perfusion pressure elevated gradually after anastomosis and significantly increased at 4 weeks post-operatively in all three methods. Various degrees of hydronephrosis were also noticed in three groups after 4 weeks of surgery.

**Conclusions:** Use of the intraluminal albumin stent increased the reliability of laser welding for ureteral anastomosis. The clinical significance of using this technique should be investigated further. *Lasers Surg. Med.* 32:294–298, 2003. © 2003 Wiley-Liss, Inc.

**Key words:** albumin; laser welding; solder; stent; ureter

## INTRODUCTION

Laser welding or soldering as a primary tissue closure technique has been investigated in urology due to its remarkable advantages, such as providing an immediate water tight closure, reducing urolithiasis, and minimizing foreign body reaction and tissue damage [1]. Investigators have described urethroplasty [2], ureteral [3] and vas deferens [4] anastomoses, and bladder [5] closure using the laser welding techniques. Using protein solders improves the reliability of laser tissue welding by enhancing strength and decreasing thermal injury. The welding strength in laser tissue soldering is dependent on solder concentration [6]. However, there are some practical issues that may limit the use of the laser techniques. For instance, the ureter must be precisely circumferentially approximated

and supported intraluminally to facilitate healing and to prevent a secondary stricture or obstruction from scar formation. Intraluminal dissolvable or absorbable stents have been reported in vascular [7] and gastrointestinal [8] anastomoses. These studies showed that use of an intraluminal dissolvable stent offered an easy sutureless anastomotic procedure and reduced foreign body irritation, and thus resulted in faster healing compared to conventional methods [8].

In our laboratory, an intraluminal albumin stent was developed to assist ureteral end-to-end anastomoses with laser welding techniques. We previously reported that using the albumin stent for laser ureteral anastomosis in vitro resulted in stronger welding strengths and higher burst pressures compared to using albumin solder alone [9]. The present in vivo study is to compare (1) laser ureteral anastomosis using an intraluminal albumin stent, (2) laser anastomosis using albumin solder, and (3) anastomosis by conventional suturing. These three anastomotic techniques were assessed by the following factors: operative parameters, leakage rate, intrapelvic perfusion pressure, urography, and histologic examinations.

## MATERIALS AND METHODS

### Preparation of Albumin Stent

The details of the preparation of albumin stent have been published previously [9]. Briefly, commercial 25% human serum albumin (Michigan Department of Public Health, Lansing, MI) was filtered through an ultrafiltration membrane (YM 30, Amicon, Beverly, MA), and concentrated to 50% (Weight/Volume) using an ultrafiltration system (Model 8400, Amicom, MA) under 35–45 psi nitrogen gas pressure at room temperature. The 50% albumin was mixed with sterile 10 mM Indocyanine Green

---

The opinions or assertions contained herein are the private views of the authors and are not to be construed as official or reflecting the views of the Department of Army or the Department of Defense. No governmental endorsement should be inferred.

Contract grant sponsor: Department of the Army; Contract grant number: DAMD 17-96-1-6006.

\*Correspondence to: Hua Xie, MD, PhD, Oregon Medical Laser Center, Providence St. Vincent Medical Center, 9555 SW Barnes Rd. Suite 210, Portland, OR 97225. E-mail: hxie@providence.org

Accepted 28 January 2002  
Published online in Wiley InterScience  
(www.interscience.wiley.com).  
DOI 10.1002/lsm.10164

(ICG, Sigma, St. Louis, MO) at 1:100 ratio (volume:volume) such that the final ICG concentration was 0.1 mM in the mixture. The albumin and ICG mixture was placed in a sealed chamber at 24°C until it became moldable as excess fluid evaporated. The albumin was then molded to produce a hollow cylinder-like stent with a 3.5 mm outer diameter, 2.0 mm inner diameter, and 1.5 cm in length. The stent was packaged in an air-tight opaque container and stored at 4°C. These storage conditions prevented photobleaching and maintained the humidity level, preventing the albumin stent from further drying and becoming brittle. The preparation was performed sterilely. The stents were used within 3 weeks of preparation.

### Preparation of Albumin Solder

The liquid solder was made with the same process as the albumin stent, but the procedure was stopped before the evaporation step. The final product of the solder consisted of 50% albumin with 0.1 mM ICG mixture. The solder was packed in a 1 cc syringe and stored in the dark at 4°C. The solder was utilized within 3 weeks of preparation.

### Laser System

Laser treatments were performed with a diode laser module (Diomed25, Diomed Limited, Cambridge, UK) coupled to a quartz silica non-contact optic fiber (600- $\mu$ m diameter). The laser system consisted of a phased array of gallium-aluminum-arsenide semiconductor diodes and the major wavelength output of the diode laser was 810 nm. The distance from optic fiber to target tissue was approximately 2–3 mm. The spot size of the laser beam on target tissue was approximately 1–2 mm<sup>2</sup>. The laser had 2.0 average watts with 0.1 seconds pulse width and 0.1 seconds interval according to previous *in vitro* result [9]. Laser operative time was recorded with a built-in laser meter monitor. Before and after welding, actual energy was measured using an energy meter (Vector H310, Scientech, CA).

### Surgical Procedures

Female domestic swine (N = 12, 15–25 kg) underwent bilateral end-to-end ureteral anastomosis using one of

the three following techniques: laser with intraluminal albumin stent, laser with albumin solder, and conventional suturing. All surgeries were preformed by one surgeon. Our surgical protocol followed the Guidelines of the Care and Use of the Laboratory Animals and was approved by the Animal Care and Use Committee of Oregon Health Sciences University.

Animals were fasted overnight and sedated with intramuscular injection of Telazol (1.0 mg/kg) followed by general endotracheal anesthesia, using 1–2% Halothane inhalant. In supine position the animal abdomen was shaved, prepped and draped in a sterile fashion. A midline laparotomy was made to expose kidneys, ureters, and bladder. An 18 G needle was placed percutaneously into the renal pelvis to monitor intrapelvic pressure before anastomosis. After the pre-operative intrapelvic pressure was recorded, a 6 to 8 cm length of mid-ureter on operative side was carefully mobilized, and a 1.5–2 cm section was resected. The proximal end of ureter was gently stretched using an umbilical tape to control urinary flow. The stretch technique was not used for the first three animals, which included two in stent groups and two in solder groups. The suture group did not apply this technique. The ends of the ureter were then spatulated and anastomosed using one of the three surgical methods selected randomly.

In the albumin stent group (N = 11), a 4.8 Fr double pigtail stent (Circon Surgitek, CA) was prepared with an albumin stent (Fig. 1), and inserted into the ureteral ends to the renal pelvis and bladder. Both ends of the ureter were then approximated over the albumin stent and irradiated with the laser. In the albumin solder group (N = 8), a 4.5 Fr double pigtail stent was inserted into the ureter, the ureteral ends were approximated, and positioned with two 6-0 polyglactin sutures. The anastomotic site was then coated externally with albumin solder and irradiated with the laser. The end point for laser welding in both groups was the visual assessment at the albumin color whitening (Fig. 2). In the suture group (N = 5), the ureteral anastomosis was accomplished by six to eight interrupted stitches with a 6-0 polyglactin suture. A 4.5 Fr double pigtail stent was placed before suture.

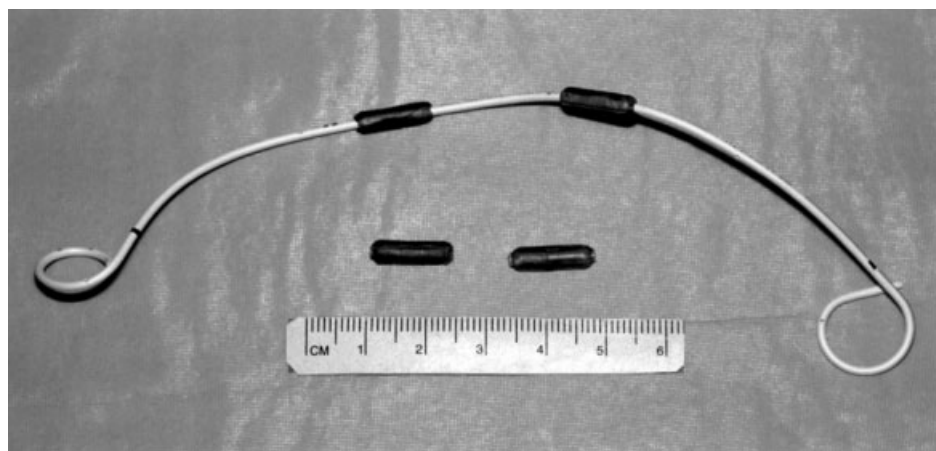


Fig. 1. Intraluminal albumin stents and an ureteric pigtail stent (4.5 Fr, 18 cm).

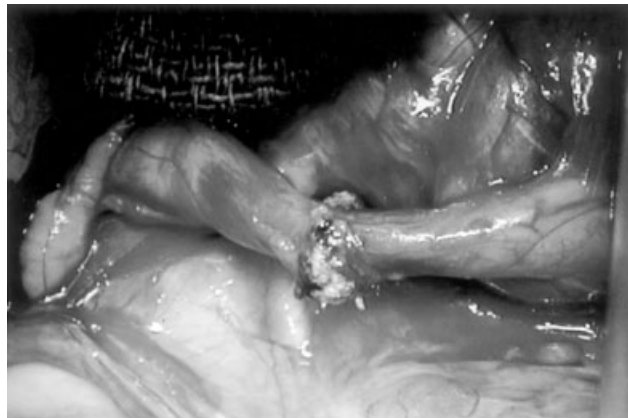

Fig. 2. An anastomosis of ureter was completed using intraluminal albumin stent with laser.

Heart rate, blood pressure, oxygen saturation, and carbon dioxide partial pressure were monitored during surgery. The anastomotic time and total laser energy were recorded. After completion of the anastomoses, the intrapelvic pressure was measured again. The bladder was then opened to place bilateral ureteral pigtail stents and an 8 Fr red rubber urethral catheter through the external urethral opening. The urethral catheter and the ureteral stents were cut short and fixed to the perineal skin with 5-0 polyglactin suture. The abdominal incision was closed in layers. The urethral catheters and the ureteral stents were removed respectively at 3 days and 14 days post-operatively. No drainage tubes were placed at the external site of the ureter anastomosis. Antibiotics (Gentamycin 4 mg/kg, Polyflex 5 mg/kg, twice a day) were given intramuscularly before surgery and post-operatively for 7 days. At 7 days after surgery, ultrasound sonography was performed to check for urinary extravasation at the anastomotic sites. When evidence of urinary leakage and/or urinoma formation was confirmed by sonography and retrograde ureteropyelography, the animal was euthanized. Blood samples were collected before surgery and at the time of sacrifice for general and renal function analyses. The intrapelvic pressure was measured at 4 weeks just prior to animal sacrifice. The ureteral specimens were harvested for histological examination.

#### Perfusion Pressure Flow Study (Whitaker Test)

To evaluate the ureteral anastomosis, a perfusion pressure flow study was modified and performed in accordance with Whitaker's description [10]. Briefly, the animals were sedated as described above. An 18G wide bore needle was percutaneously inserted on both sides of renal pelvis. The measurement of intrapelvic pressure was taken from each side of renal pelvis individually. After recording the baseline of intrapelvic pressure, the peak of intrapelvic pressure was measured at an infusion rate of 10 ml/min with Ringer solution. The antegrade ureteropyelography was performed with a mixture of Ringer solution and contrast medium (RenoCal-76, Bracco Diagnostics) to

evaluate the morphology of the pelvis and ureter. The intrapelvic pressures above baseline were obtained before, immediately after, and at 4 weeks after anastomosis.

#### Histology

The specimens were immediately placed in 10% buffered formalin for fixation. Histological sections of the ureteral tissue were obtained from each repair and stained with hematoxylin-eosin stain.

#### Statistics

The operative time was compared among the groups using the Kruskal Wallis test. The Mann-Whitney U test was used to compare laser energy between stent and solder groups. The Bonferroni multiple comparisons were done for intrapelvic pressures for each of the groups and time intervals. Statistical significance was assigned to *P* values less than 0.05.

#### RESULTS

Of the 12 pigs (24 anastomoses), 3 had unilateral urinoma formation and were sacrificed 7 days after surgery. The urinomas were associated with stent ( $N = 1$ ) and solder ( $N = 2$ ) anastomoses. Due to the bilateral nature of the study, three normal anastomoses were lost at this time point as well (suture  $N = 1$  and stent  $N = 2$ ). Remaining pigs (18 anastomoses) continued for the full 4 week study. These included eight ureteral anastomoses using the albumin stent and laser, six using the albumin solder and laser, and four with the sutures. Blood laboratory analysis showed that blood white cell count (WBC), urea nitrogen (BUN), and serum creatinine (Cr) were normal in the animals 4 weeks post-operatively.

The operative time of ureteral anastomosis of using stent and solder were significantly shorter than that of using suture (both  $P = 0.02$ ). The total energy used in the stent group was similar to the solder group. The urinoma formation in the stent and solder groups was 9% and 25%, respectively. The summarized results are listed on Table 1.

The Whitaker test showed that the intrapelvic perfusion pressures gradually increased in all groups after surgery (Fig. 3). However, the only significant change was found between pre-operatively and at 4 weeks after surgery in all groups ( $P = 0.02$ ). There were no significant differences in intrapelvic pressure among the groups for the same time point. The antegrade urography showed various degrees of hydronephrosis was present in all groups. This was not related to obvious blockage in the urinary pathway 4 weeks post-operatively.

Histological examination showed a mild post-surgical adhesion and a localized inflammatory response in all groups. Subjectively, less local adhesion and fibrosis were found in the stent and solder groups than the sutures group. In the suture group the remarkable inflammatory responses were associated to the degradation process of suture remnants. There was no evidence of albumin remnants in the stent and solder groups. The transitional epithelia evidently covered all anastomoses by 4 weeks

**TABLE 1. Summary of Operative Parameters and Outcomes of the Ureteral Anastomoses**

Group	Number of ureters	Operative time (sec)	Total energy (J)	Urinoma w/o urine control (N/N)	Urinoma with urine control (N/N)
Stent	11	370 ± 190	110 ± 60	1/2	0/9
Solder	8	360 ± 130	130 ± 50	2/2	0/6
Suture	5	710 ± 200 <sup>a</sup>		0/5	

Values are Mean ± SD.

<sup>a</sup>Significant differences from suture versus stent and solder, both  $P = 0.002$ .

after surgery. At the anastomotic site, fibrous scar tissue was deposited with neovascularization, but no evidence of muscular regeneration was observed.

## DISCUSSION

Ureteral repairs require a watertight, tension-free anastomosis along with precise tissue apposition to minimize tissue scarring and stricture formation. Potentially laser tissue welding could theoretically provide such a repair. Our study showed that using an albumin stent was more efficient than using albumin solder alone for ureteral laser anastomosis (e.g., higher burst pressures and tensile strengths) [9].

Urinary leakage or extravasation was the cause of urinoma formation. Clinically, urinary extravasation can be managed by drainage, but this is impractical in the porcine model. We noticed extravasation was associated with the cases in which the albumin stent and solder were dissolved and removed by urine before the anastomosis was completed. We then modified surgery to use umbilical tape to gently stretch the proximal end of the ureter to decrease urine flow. No urinoma occurred in those late cases.

In this study, we also observed various degrees of hydronephrosis in all groups 4 weeks after surgery. However, the ureteropyelography study did not reveal substantial evidence of ureteral obstruction or stricture. The laboratory

results indicated no significant changes in BUN and Cr from pre-surgical values (data not shown). The Whitaker test showed that the intrapelvic pressure elevated gradually with a significant increase from pre-operative values to 4 weeks post-surgery in all groups. In accordance with Mortensen et al. measurements, which the intrapelvic pressure were within the normal range [11]. The exact cause of hydronephrosis remains unclear since the ureteral stents were in place, which should have protected the upper tracts from obstruction. Initial concerns that residual intraluminal denatured albumin might lead to partial obstruction of the ureter or urinary stone formation were unfounded. None of the ureters in our studies demonstrated any apparent obstruction by an albumin remnant after surgery. Additionally, histological examination found no albumin residuals in any anastomotic site 4 weeks after surgery. In the suture group, a remarkable inflammatory reaction was presented in the ureteral anastomotic site that was associated with suture remnants. However, there was no evidence that this post-operative inflammation was related to the hydronephrosis in the suture group. One possibility, perhaps, is the repeated transmission of bladder pressure back to the kidney during spontaneous micturition. Finally, the effect of ureteral stents in this growing animal model is unclear, and change in size could potentially cause upper urinary tract dilatation.

In conclusion, the intraluminal albumin stent assisted laser welding is an efficient method for ureteral end-to-end anastomosis. The technique can be applied for other tubular organ anastomosis, such as urethra, vascular and intestinal, and so forth. Future studies will look at modifying the albumin stent for use with other lasers and applications.

## ACKNOWLEDGMENTS

The authors express gratitude to Jeff Teach, RN, Victoria Feldman for surgical assistance. They also thank Allen Burke, MD of Armed Forces Institute of Pathology for histology evaluation, Barry Uchida and Dusan Panvik, MD of Charles Dotter Institute, and Ying Wu, MD of Pediatric Ultrasound Lab of Oregon Health Sciences University for ureteropyelography and ultrasound sonography assistance, and Gray Grunkemeier, PhD for statistical analysis.

## REFERENCES

1. Kirsch AJ. Laser tissue soldering: State of the art. *Cont Urol* 1997;8:41-60.

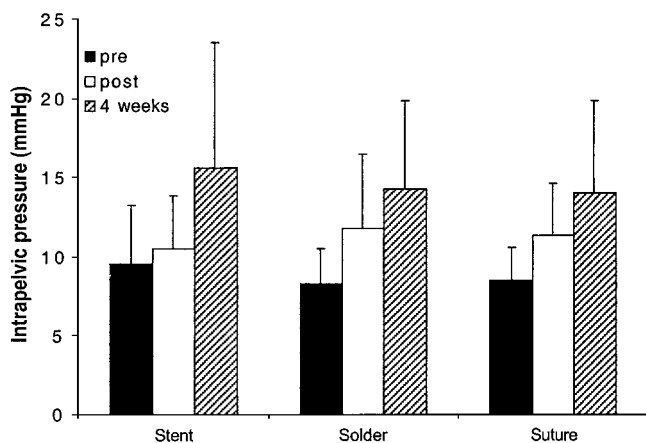


Fig. 3. Intrapelvic perfusion pressure study: intrapelvic pressure measured at 10 ml/min perfusion. Mean pressures ± standard deviations are illustrated. Significant difference from preop versus 4 weeks.

2. Poppas DP, Schlossberg SM, Richmond IL, Gilbert DA, Devine CJ Jr. Laser welding in urethral surgery: Improved results with a protein solder. *J Urol* 1988;139:415-417.
3. Wolf JS, Soble JJ, Nakada SY, Rayala HJ, Humphrey PA, Clayman RV, Poppas DP. Comparison of fibrin glue, laser weld, and mechanical suturing device for the laparoscopic closure of ureterotomy in a porcine model. *J Urol* 1997;157:1487-1492.
4. Kirsch EB, Seidmon EJ, Samaga AM Jr, Phillips SJ, Tang CK, Shea FJ. Carbon dioxide milliwatt laser in the vasovasostomy of vas deferens in dogs: Part I. *Lasers Surg Med* 1990;10:328-333.
5. Lobik L, Ravid A, Nissenkorn I. Bladder welding in rats using controlled temperature CO<sub>2</sub> laser system. *J Urol* 1999;161:1662-1665.
6. Wright EJ, Poppas DP. Effect of laser wavelength and protein solder concentration on acute tissue repair using laser welding: Initial results in a canine ureter model. *Tech Urol* 1997;3:176-181.
7. He FC, Wei LP, Lanzetta M, Owen E. Assessment of tissue blood flow following small artery welding with an intraluminal dissolvable stent. *Microsurg* 1999;19:148-152.
8. Detweiler MR, Durastante V, Verbo A, Muttillio I, Piantelli H, Kobos JW, Antinori A, Granone P, Magistrelli P, Picciochi A. Sutureless anastomosis of the small intestine and the colon in pigs using an absorbable intraluminal stent and fibrin glue. *J Invest Surg* 1995;8:129-140.
9. Xie H, Shaffer BS, Prahla SA, Gregory KW. Intraluminal albumin stent assisted laser welding for ureteral anastomosis. *Lasers Surg Med* 2002;31:225-229.
10. Whitaker RH. Perfusion pressure flow studies. In: O'Reilly PH, George NJ, Weiss RM, editors. *Diagnostic techniques in urology*. Darien, IL: W. B. Saunders Company, 1990. 135-139.
11. Mortensen J, Djurhuus JC, laursen H, Bisballe S. The relationship between pressure and flow in the normal pig renal pelvis: An experimental study of the range of normal pressures. *Scand Urol Nephrol* 1983;17:369-372.